

Diagnostic approaches and treatments of systemic sclerosis patient with interstitial lung disease



Fauziah Diayu Retnaningtyas^{1,2}, Awalia^{3,4*}

ABSTRACT

Background: Systemic sclerosis or scleroderma is a rare disease with multiple complications which may include interstitial lung disease. The findings of diffuse type of systemic sclerosis, moderate restriction in pulmonary function test, interstitial pneumonia in chest x-ray, and ground glass opacity in thoracic CT-scan establish the diagnosis of interstitial lung disease associated with systemic sclerosis. We present a case of interstitial lung disease in a systemic sclerosis case, which was approached and treated comprehensively to slow the progression.

Case Presentation: A 40-year-old female was admitted to the rheumatology polyclinic of Dr. Soetomo Hospital Surabaya with persistent dry cough for two years in June 2021. The patient also complained of breathlessness, painful joints, swollen knees, and morning stiffness three months prior to admission. The positive results of antinuclear antibody and rheumatoid factor were identified in 2016, which suggested autoimmune disease of scleroderma and being treated with azathioprine 50 mg twice a day, methylprednisolone 4 mg once a day, chloroquine 200 mg once a day, and calcium lactate once a day. The examinations in 2020 showed moderate restriction from the pulmonary function test, bilateral lung parenchymal infiltrates from the chest x-ray, and ground-glass opacity from the chest computed tomography scan (CT-scan). The patient was monthly prescribed cyclophosphamide 500 mg intravenously for six months as the substitution of azathioprine, methylprednisolone 4 mg once a day, and aspirin 100 mg once a day. The latest worsening condition led the patient to receive the substitution of cyclophosphamide which was mycophenolate mofetil 360 mg twice a day, along with aspirin 100mg and methylprednisolone 4 mg once a day, respectively.

Conclusion: As a rare disease, the complications of systemic sclerosis should be anticipated. In this case, interstitial lung disease occurred following nearly five years of systemic sclerosis course which required immunosuppressive agents to enhance the efficacy of treatment. Comprehensive treatment with tight monitoring is necessary to slow the disease progression.

Keywords: Systemic sclerosis, scleroderma, ground-glass opacity, interstitial pneumonia, mycophenolate mofetil.

Cite This Article: Retnaningtyas, F.D., Awalia. 2024. Diagnostic approaches and treatments of systemic sclerosis patient with interstitial lung disease. *Bali Medical Journal* 13(1): 877-881. DOI: 10.15562/bmj.v13i1.5225

¹Department of Internal Medicine, Faculty of Medicine, Universitas Airlangga, Surabaya, Indonesia

²Department of Internal Medicine, Faculty of Medicine, Dr. Soetomo General Academic Hospital, Surabaya, Indonesia

³Division of Rheumatology, Department of Internal Medicine, Faculty of Medicine, Universitas Airlangga, Surabaya, Indonesia

⁴Division of Rheumatology, Department of Internal Medicine, Faculty of Medicine, Dr. Soetomo General Academic Hospital, Surabaya, Indonesia

*Corresponding to:

Awalia, Division of Rheumatology, Department of Internal Medicine, Faculty of Medicine, Universitas Airlangga-Dr. Soetomo General Academic Hospital, Surabaya, Indonesia;
awalia@fk.unair.ac.id

Received: 2023-11-26

Accepted: 2024-01-27

Published: 2024-02-24

INTRODUCTION

Systemic sclerosis, or scleroderma, is a rare disease with an unknown etiology and complex pathophysiology.¹ Systemic sclerosis is identified with a dysfunctional immune system, vasculopathy, altered cell-mediated immunity, and fibrosis of the skin and several internal organs.² This disease is suspected based on clinical features which are matched to specific serological findings.³ The incidence of this disease is around 8 to 56 cases per one million people, with a prevalence of 38 for every 341 cases per one million people. The incidence of scleroderma in the world has a range around 18 to 20 cases for every one million population, with more cases found in the United States than in Europe,

with African-American having a higher incidence of severe cases than other races.⁴

As an autoimmune disease with heterogeneous pathogenesis, systemic sclerosis may manifest as vasculopathy, autoantibody formation, and fibroblast dysfunction that cause extracellular matrices deposition.⁵ Most patients are women of younger age, accompanied by peripheral vascular disease and pulmonary artery hypertension. In men, systemic sclerosis are more diffused, causing pulmonary disorders and cardiovascular complications.⁶

Pulmonary disorders due to systemic sclerosis generally manifest as interstitial lung disease, which corresponds to 40% of all deaths related to systemic sclerosis, with the rest is mostly caused by pulmonary

artery hypertension (50%).^{2,3,7,8} Interstitial lung disease in systemic sclerosis is diagnosed during the initial phase of scleroderma (25%) through physical examination, x-ray, and CT-scan.⁹ Risk factors of interstitial lung disease in systemic sclerosis include diffuse type of scleroderma, African-American race, old age, and the existence of anti Scl-70 or anti-topoisomerase-1 autoantibody.³

Clinical manifestations of interstitial lung disease include dyspnea, fatigue, and dry cough. Physical examination may present rales or rhonchi in the base of the lungs, which are also known as "Velcro rales".¹⁰ Laboratory findings of anti-Scl-70 or anti-topoisomerase-1 autoantibody are strong evidence of interstitial lung disease in systemic sclerosis patients,

while anticentromere antibody findings are related to limited cutaneous systemic sclerosis with pulmonary artery hypertension.¹¹

The recommended treatment of scleroderma with pulmonary manifestation is non-selective immunosuppressive therapy.² Based on the theory that scleroderma is an autoimmune disease mediated by T cells, immunosuppressive therapy has been utilized to treat this disease for more than 30 years. The immunosuppressive medications that are most frequently used in scleroderma patients are mycophenolate mofetil, azathioprine, cyclophosphamide, and methotrexate. Immunosuppressive agents have to be monitored regularly to avoid the adverse effects which mainly contribute to the weakening of the immune system and vulnerability to infections. An immunosuppressive agent should be substituted with the other immunosuppressive agents once indicating intolerance on the patient.^{7,8,12} This study reports female patient with scleroderma who developed interstitial lung disease and required the replacement of several immunosuppressive agents to control the disease progression.

CASE PRESENTATION

A woman, aged 40 years old, a housewife, was admitted to the rheumatology outpatient clinics of Dr. Soetomo Hospital, Surabaya on June 6th 2021 with recurring dry cough since April 2019. The patient also felt breathless after a long walk. She had gone to a primary health care facility but the symptoms did not recede. Complaints about painful joints of hands, swollen knees and morning stiffness around two hours after waking up were felt in the last two to three months.

The medical history consisted of hair loss of the armpit and legs, darkening skin accompanied with white spots resembling "salt and pepper" appearance around the chest and back (Figure 1), painful joints, swollen and stiff fingers since 2016. Previous laboratory results showed increased titers of antinuclear antibodies (319.4), C3 (12.5), and C4 (49). Rheumatoid factor and anti-MOU were positive. During the control, the patient was treated with azathioprine 50 mg twice

a day, along with methylprednisolone 4mg, chloroquine 200 mg, and calcium lactate once a day, respectively.

When the patient came for control to the polyclinic in 2020, the patient complained bluishness and paling on the right index finger and coldness throughout the fingers without pain. The patient was diagnosed with Raynaud's phenomenon. In August 2020, the patient returned with the same but worsening complaints since a month before. Chest x-ray revealed lungs inflammation. Spirometry showed vital capacity (VC) 47.81%, functional vital capacity (FVC) 47.81%, forced expiratory volume (FEV₁) 55.27%, FEV₁/FVC 100%, which was interpreted as moderate restriction without obstruction. The patient received fenoterol hydrobromide spray but reported no improvements. The second chest x-ray revealed a reticular pattern around the right paracardiac lung field indicating interstitial pneumonia. Non-contrast chest CT scan showed ground-glass opacification with interstitial thickening. The patient was diagnosed with interstitial lung disease related to scleroderma (Figure 2). The prescription was renewed in December 2020 into cyclophosphamide 500 mg IV every month for 6 times, methylprednisolone 4

mg once a day, and aspirin 100 mg once a day.

In February 2021, the patient was planned for the third cyclophosphamide injection but was delayed due to a positive PCR test for COVID-19. Since the COVID-19 was asymptomatic, the patient was voluntarily isolated at home for two weeks. On February 18th, the patient returned for control and was quickly referred to the pregnancy polyclinic following the pregnancy confirmation. Further multidisciplinary case discussion between the expert ruled that continuing pregnancy will risk the condition of the patient and the viability of the fetus. The obstetrician decided pregnancy termination by spontaneous abortion.

On the recent physical examination, the Glasgow Coma Scale (GCS)15, blood pressure 110/70 mmHg, heart rate 90 times/minute, respiratory rate 20 times/minute, and axilla temperature of 37°C. Oxygen saturation was 96% in free air. Wong-Baker Pain Rating Scale was 0. The skin seemed to be tightening on the face, brachialis, around the clavicle, and the axilla. Other physical findings are unremarkable. The thoracal examination was in normal limit, except the auscultation revealed rhonchi from both sides of basal

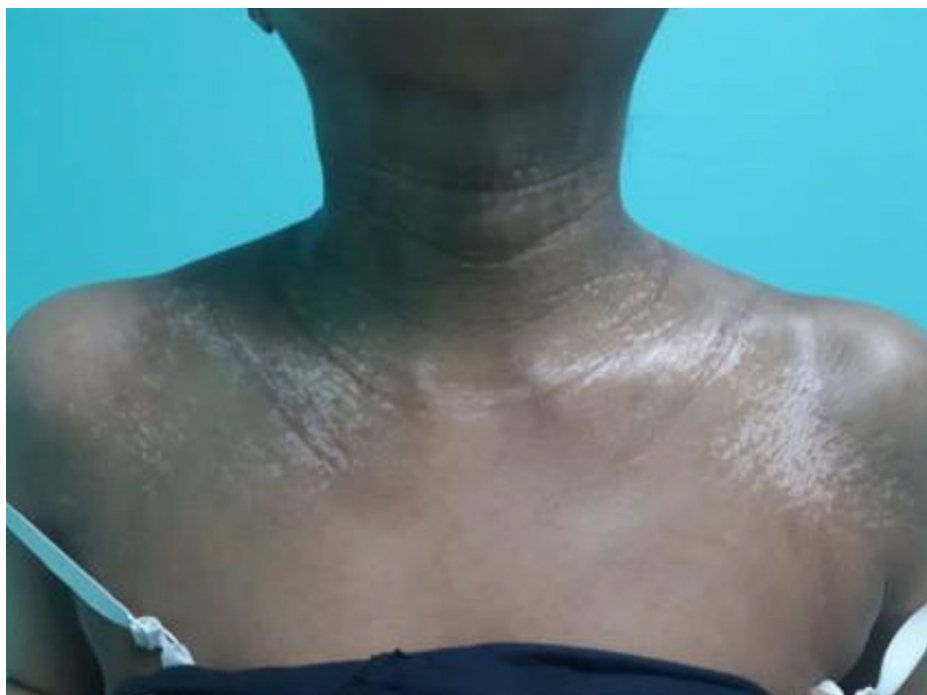

Figure 1. Salt-and-pepper appearance is skin manifestation characterized by hyperpigmentation and hypopigmentation in the sclerotic area.

hemithorax. Gait, Arm, Leg and Spine (GALS) screening showed normal results.

Laboratory tests showed normal hemoglobin, thrombocyte, slight increase of leukocyte (11.260), slight decrease of hematocrit (41.1%), slight increase of neutrophil (71.8%), decreased lymphocyte 16.4 %, decreased eosinophil 0.1 %, normal monocyte, basophil, blood urea nitrogen, creatinine serum, estimated glomerular filtration rate, random blood glucose, alanine aminotransferase (ALT) and aspartate aminotransferase (AST) levels, sodium, potassium, chloride, and albumin. Urinalysis result was within the normal limit. Chest x-ray still revealed bilateral infiltrates in the lower lobes of the lungs (Figure 3). The echocardiogram showed the ejection fraction, all valves, and chambers were normal.

The above findings supported the diagnosis of systemic sclerosis with interstitial lung disease. The diet for the patient was a high calorie and high protein of 1900 kcal/day. The patient also received her fourth cyclophosphamide infusion of 500 mg IV, methylprednisolone 4 mg, and aspirin 100 mg once a day. The initiation of mycophenolic acid was delayed.

On the third day after the fourth infusion, no complaints were reported. Physical findings were within normal parameters. The patient received methylprednisolone 4mg and aspirin 10 mg. On the fifteenth day, the patient complained of skin tightness, and persistent dry cough, albeit in lower frequency. The patient had no shortness of breath. Laboratory test showed normal hemoglobin, leucocyte, thrombocytes, increased erythrocyte sedimentation rate (62 mm/hour), normal random glucose test, increased AST (107 U/L) and ALT (135 U/L), decreased blood urea nitrogen (7 mg/dl) and creatinine serum (0.4 mg/dl). The patient was prescribed mycophenolic acid 360 mg twice a day, methylprednisolone 4mg once a day and the next cyclophosphamide infusion was delayed.

DISCUSSION

Our study presents a 40-year-old woman complaining of a dry cough in the last two years before admission. These complaints were worsened by shortness

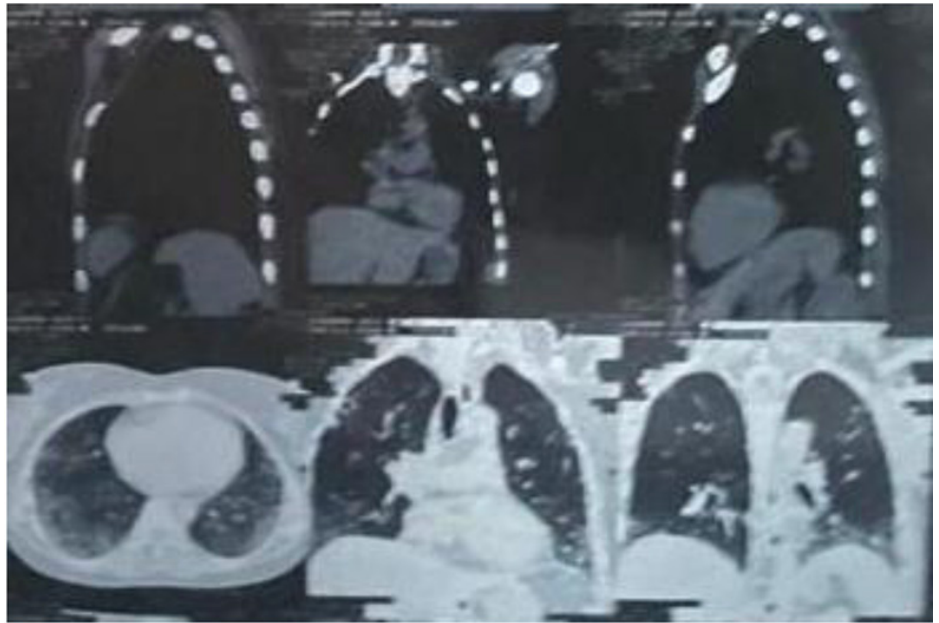


Figure 2. The non-contrast chest CT scan demonstrated ground glass opacity with interstitial thickening.

of breath following moderate activity and morning stiffness in the past three months. The patient was diagnosed with systemic sclerosis in the past 5 years due to positive results of antinuclear antibody and rheumatoid factor, following the manifestations of darkening skin with “salt and pepper” appearance, hair loss, and painful joints. Bilateral interstitial pneumonia was identified through chest x-ray and CT-scan one year ago, which is one of systemic sclerosis complications.

The onset of the disease ranges around the age of 35 to 50 years with higher frequency on women at a ratio of 3-7:1 compared to men, as some other autoimmune diseases affect women more frequently.^{4,6,10,13} The main cause of scleroderma consists of genetic and environmental factors which include ingesting food suspected to contain high level of L-tryptophan, having occupation susceptible to contact with materials containing trichloroethylene, xylene, poly-vinyl chloride, and silicate powder, as a reaction to medications such as bleomycin, paclitaxel, docetaxel and cocaine, and radiation from radiotherapy treatment.² Our patient is 40 years old but has been diagnosed with scleroderma for 5 years. The risk factor of this disease is genetic since the patient’s occupation as a housewife and no past medical history of

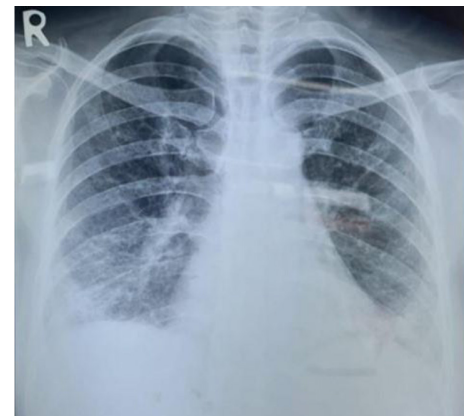

Figure 3. The chest x-ray showed bilateral parenchymal infiltrates in the lower lobes, indicating interstitial lung disease.

taking medication prior to the disease is related to the pathogenesis.

Systemic sclerosis is divided into two main types, limited and diffuse cutaneous systemic sclerosis.⁷ Limited cutaneous systemic sclerosis can be diagnosed when diagnostic criteria of scleroderma is met which involves distal limbs, such as below the elbow and the knee. Diffuse cutaneous systemic sclerosis has different manifestations that show skin thickening in the proximal axillary and axial body. A score of more than nine (≥ 9) in the ACR-EULAR 2013 study indicates a diagnosis of systemic sclerosis.⁵ This patient had

a score of 18 based on the ACR-EULAR criteria of systemic sclerosis. This score was summed up from the findings of skin thickening from the hands to the proximal metacarpal-phalanges, with evidence of sclerodactyly, interstitial lung disease, and Raynaud's phenomenon. This patient was considered to have diffuse cutaneous systemic sclerosis since the skin involved included the face, hands, thighs, proximal axilla, and around the clavicle.

Skin alteration is the common manifestation of systemic sclerosis, although other organs such as the cardiopulmonary, gastrointestinal, renal and the musculoskeletal systems can also be involved.¹⁰ Skin alteration usually shows thickening and tightening of the skin which a modified Rodnan scoring can grade, while patient may complain of itch, "pins and needles" pain, dry skin, small papules with a cobblestone texture, perifollicular pigmentation, "salt and pepper appearance", vitiligo, skin ulceration in the end of fingers, sclerodactyly and telangiectasia of the hands, face, fingers and other mucosa of the body.^{7,14} As reported in this study, the patient experienced skin thickening and sclerodactyly.

Pulmonary function tests and radiological findings are useful for recent onset or early progression of the disease. Spirometry detects forced expiratory volume in 1 second (FEV_1) and forced vital capacity (FVC), both used to detect restriction ($FEV_1/FVC < 0.7$ or $FVC < 80\%$ or $\Delta FVC > 10\%$). Problems in lung diffusion can be detected with diffusion capacity for carbon monoxide (DLCO) $< 70\%$ or $\Delta DLCO > 15\%$.¹⁵ Radiological findings using x-ray may show symmetrical reticular and ground glass opacity appearance. High-resolution CT scan detects non-specific interstitial pneumonia (NSIP) with ground glass opacity distributed in the periphery. Reticular opacity, centrilobular fibrosis, bronchiectasis (honeycomb appearance), and cystic formation of the lungs are rare and progressive manifestations of late-onset interstitial lung disease.¹⁰ Our patient had FVC 47.81% in 2020 and FVC 47.57% in 2021, which suggested a moderate restriction. The x-ray findings in both years also revealed interstitial pneumonia.

Thoracic CT-scan in 2020 revealed ground glass opacity in the peripheral base of the lungs, indicating interstitial lung disease.

Scleroderma should be treated with cyclophosphamide, either orally or intravenously, until the patient's condition is controlled.¹⁰ After cyclophosphamide, azathioprine or mycophenolate mofetil is given as a substitute. Mycophenolate mofetil is commonly used as the first-line treatment for scleroderma with interstitial lung disease, while azathioprine has lower efficacy despite limited studies.^{11,16} Methotrexate is another immunosuppressant used only if the patient has arthritis or myositis, while selective immunosuppressants such as cyclosporine, sirolimus, or rituximab are shown to improve skin conditions and stabilize pulmonary function although related studies are still limited.¹⁰ The patient received cyclophosphamide intravenously for three doses but was stopped due to increased liver enzymes, therefore the medication was substituted with mycophenolate mofetil.

The antifibrotic agent is additionally prescribed to prevent the progression of interstitial lung disease.^{17,18} Vasculopathy should also be a concern as a pathogenetic factor in scleroderma-related tissue damage. Raynaud's phenomenon can be treated with calcium channel blockers and aspirin.¹⁰ Supportive therapy in relation to gastroesophageal reflux disease (GERD) due to dysmotility of the esophagus in scleroderma patients will need proton pump inhibitor (PPI) and prokinetic agents (metoclopramide and domperidone).¹⁷ The patient in this study received 100mg of aspirin once a day and did not receive PPI as no GERD symptoms were reported.

Pulmonary artery hypertension is a frequent complication due to scleroderma-related interstitial lung disease.¹⁶ Monthly clinical and laboratory examinations, including pulmonary function tests, x-rays every 3 months, and thoracic CT scans every 6 months, should be monitored.⁸ Poor prognosis is often seen in male patients with old age, diffuse cutaneous systemic sclerosis, increased reaction during acute phase, shortness of breath, interstitial lung disease in radiological examination, lowered FVC, renal crisis,

low ejection fraction, digital ulcers, and joint involvement.¹⁵ In this study, echocardiography of the patient revealed normal valves and dimensions of the four chambers. Physical and laboratory monitoring of the patient were conducted every month, while pulmonary function tests and CT scans were planned every 6 months. Our patient has a poor prognosis due to diffuse type of systemic sclerosis, erythrocyte sedimentation rate over 62 mm/hour, and FVC 47,57%.

CONCLUSION

Interstitial lung disease is one of the most anticipated complications of systemic sclerosis. As a rare disease, systemic sclerosis should be treated and monitored comprehensively to prevent the complications. Our study reports a 40-year-old female patient complaining persistent dry cough in the past two years before admission. The additional complaints were shortness of breath, morning stiffness, and painful joints in the last three months. Medical history recorded diffuse cutaneous systemic sclerosis five years ago. The recent examinations demonstrated moderate restriction in pulmonary function test, interstitial pneumonia in chest x-ray, and ground glass opacity in thoracic CT-scan, which suggested our patient was diagnosed with interstitial lung disease related to systemic sclerosis. The patient received mycophenolate mofetil, aspirin, and methylprednisolone. The mycophenolate mofetil was prescribed as substituting the previously given immunosuppressive agents like cyclophosphamide and azathioprine. Systemic sclerosis with interstitial lung disease requires tight monitoring and suitable immunosuppressive therapy to slow the disease progression.

CONFLICTING INTEREST(S)

The authors declare that there are no conflicts of interest.

FUNDING

The authors received no specific funding for this work.

ACKNOWLEDGMENTS

The authors thank Dr. Soetomo General-Academic Hospital and Medical Faculty of Universitas Airlangga, Surabaya, Indonesia.

AUTHOR CONTRIBUTION

All authors had contributed to manuscript writing and agreed for the final version of manuscript for publication.

ETHICAL CONSIDERATION

The patient had received signed written informed consent regarding publication of medical data in scientific medical journals with confidentiality of personal information.

REFERENCES

- Rosendahl AH, Schönborn K, Krieg T. Pathophysiology of systemic sclerosis (scleroderma). *Kaohsiung J Med Sci.* 2022;38(3):187-195.
- Frans JV. Etiology and Pathogenesis of Scleroderma. In: Firestein G BR, Gabriel S, McInnes I, O'Dell J, ed. *Kelley & Firestein's Textbook of Rheumatology* 10th Edition. Philadelphia: Elsevier; 2017: 1400–23.
- Cottin V, Brown KK. Interstitial lung disease associated with systemic sclerosis (SSc-ILD). *Respiratory research.* 2019;20:1-10.
- Peoples C, Medsger Jr TA, Lucas M, Rosario BL, Feghali-Bostwick CA. Gender differences in systemic sclerosis: relationship to clinical features, serologic status and outcomes. *Journal of scleroderma and related disorders.* 2016;1(2):204-12.
- Johnson SR. New ACR EULAR guidelines for systemic sclerosis classification. *Current rheumatology reports.* 2015;17:1-8.
- Anggoro A, Hasan H. Interstitial lung disease in Indonesian adult with systemic sclerotic: A rare case. *Annals of Medicine and Surgery.* 2022;75:103386.
- Allanore Y, Simms R, Distler O, et al. Systemic sclerosis. *Nature reviews Disease primers.* 2015;1(1):1-21.
- Hax V, Bredemeier M, Moro ALD, et al. Clinical algorithms for diagnosing and prognosis interstitial lung disease in systemic sclerosis. *Seminars in Arthritis and Rheumatism;* 2017: Elsevier; 2017. p. 228-34.
- Solomon AW, Peeling RW, Foster A, Mabey DCW. Diagnosis and Assessment of Trachoma. *Clinical Microbiology Reviews.* 2004;17(4):982-1011.
- Wigley FM, Boin F. Clinical features and treatment of scleroderma. *Kelley and Firestein's Textbook of Rheumatology:* Elsevier; 2017:1424-60.
- Gutsche M, Rosen GD, Swigris JJ. Connective tissue disease-associated interstitial lung disease: a review. *Current respiratory care reports.* 2012;1:224-32.
- Hidayat R, Isbagio H, Ariane A, et al. Characteristics of patients with autoimmune rheumatic disease in the era of COVID-19 pandemic in Indonesia. *Indonesian Journal of Rheumatology.* 2020;12(1):1-9.
- Ginting AR, Tandiono V. Polymyositis concomitant with hepatitis B virus infection: Treatment challenges. *Narra J,* 2023;3(3):e514-e.
- Kamadajaja MJK, Pertiwi FN. Prosthodontic Management of a Completely Edentulous Patient with Microstomia and Flat Ridge Mandible: A Case Report. *Acta Medica Philippina.* 2019;53(6):1-8.
- Suliman YA, Dobrota R, Huscher D, et al. Pulmonary function tests: high rate of false negatives in the early detection and screening of scleroderma interstitial lung disease. *Swiss Medical Weekly;* 2015: Emh Swiss Medical Publishers Ltd Farnsburgerstr 8, Ch-4132 Muttenz, Switzerland; 2015. P. 9s-S.
- Naidu G, Sharma SK, Adarsh M, et al. Effect of mycophenolate mofetil (MMF) on systemic sclerosis-related interstitial lung disease with mildly impaired lung function: a double-blind, placebo-controlled, randomized trial. *Rheumatology International.* 2020; 40(2):207-16.
- Distler O, Highland KB, Gahlemann M, et al. Nintedanib for systemic sclerosis-associated interstitial lung disease. *New England Journal of Medicine.* 2019;380(26): 2518-28.
- Bernstein EJ, Peterson ER, Sell JL, et al. Survival of adults with systemic sclerosis following lung transplantation: a nationwide cohort study. *Arthritis & rheumatology.* 2015; 67(5):1314-22.



This work is licensed under a Creative Commons Attribution